

## The Use of Foam Sclerotherapy for Varicose Veins: A Survey of the Members of the Vascular Society of Great Britain and Ireland

J.L. O'Hare and J.J. Earnshaw\*

Gloucestershire Royal Hospital, UK

**Objectives.** The aim was to explore the current experience and practice of vascular surgeons in the United Kingdom and Ireland regarding foam sclerotherapy for varicose veins.

**Method.** A postal questionnaire was sent to 609 members of the Vascular Society of Great Britain and Ireland.

**Results.** There were 281 responses (47%). Seventy surgeons (25%) used foam sclerotherapy. Most use it selectively; few (29%) offer it to all patients. It was more likely to be used for recurrent varices (71%), in older patients (61%) and for smaller non-saphenous varices (67%). The majority of surgeons (69%) used sodium tetradecyl sulphate and up to a maximum of 10–12 ml of foam. The majority used ultrasound guidance (95%), leg elevation (69%) and direct pressure over the saphenofemoral or saphenopopliteal junction during injection (63%). Eighty per cent used compression bandaging after treatment, usually for 7 days (44%). Ninety per cent advised compression stockings, usually Class II (64%) for 14 days (39%). Serious complications were few, but eleven surgeons had seen a deep vein thrombosis, two had seen a patient with a stroke and one a transient ischaemic attack.

**Conclusion.** Foam sclerotherapy was used by a quarter of surgeons who replied to the survey. Aspects of technique varied considerably and studies to determine optimal techniques are needed. Serious complications with the technique were rare.

**Keywords:** Foam sclerotherapy; Varicose veins; Technique; Complications.

### Introduction

Surgery remains the standard treatment for symptomatic and complicated varicose veins.<sup>1</sup> However, there are a number of new endovenous techniques that are under investigation. The use of foam sclerotherapy as an alternative to surgery is gaining in popularity. Although foam treatment was reported as long ago as 1939 by Stuard McAusland<sup>2</sup> the most widely used method of foam production was described by Tessari in 2001.<sup>3</sup> It is therefore a new and evolving technique. At a European consensus meeting in 2003<sup>4</sup> an attempt was made to harmonise opinion and define principles of safe and effective practice. A recent report of ischaemic stroke after foam sclerotherapy in a patient with a patent foramen ovale<sup>5</sup> has focussed attention on the potential for embolic complications. The aim of this survey was to explore the current experience and practice of members of the Vascular Society of Great Britain and Ireland with

regard to foam sclerotherapy for the treatment of varicose veins.

### Materials and Methods

A postal questionnaire was sent to 609 members of the Vascular Society during May 2006. The questionnaire sought information about their use of foam sclerotherapy, the indications, the technique used including post-treatment compression, and the complications clinicians had seen. Not all questions were answered by every respondent.

### Results

A total of 281 completed questionnaires were returned with a further 11 returned unopened giving a response rate of 47%. Of those who replied, 70 surgeons (25%) had used foam sclerotherapy in the treatment of varicose veins. Analysis was carried out on the results of these 70 postal questionnaires. The majority of those who replied had performed fewer than 100 foam treatments; only very few had performed

\*Corresponding author. Mr. J.J. Earnshaw, Gloucestershire Royal Hospital, Department of Surgery, Great Western Road, Gloucester GL1 3NN, UK.

E-mail address: [jonathan.earnshaw@glos.nhs.uk](mailto:jonathan.earnshaw@glos.nhs.uk)

a larger number. The median number of treatments undertaken was 35 (range 1–2000).

*Patient selection*

Few surgeons (20 of 69 surgeons who responded, 29%) offered foam sclerotherapy to most patients with varicose veins. However, only 18 of 68 (26%) reserved it for those unfit for, or refusing surgery. The majority recommended it selectively for patients with recurrent varices (49 of 69, 71%), to older patients (42 of 69, 61%) and to those with smaller non-saphenous varices (47 of 70, 67%). Sixty-four percent (43 of 67) used foam sclerotherapy to treat patients with a venous leg ulcer. Twenty-three of 66 (35%) tended to avoid foam in very obese patients, where phlebitis can be a problem.

*Sclerosant foam*

The majority of surgeons (48 of 70, 69%) used sodium tetradecyl sulphate (STD) as the sclerosant. Sixteen percent of surgeons (12 of 70) used polidocanol and the remaining ten (14%) made use of both agents. All but one used the Tessari method of foam production.

The most commonly used sclerosant concentration for truncal varices was 3% for both STD (39) and Polidocanol (10) although significant numbers used 1–2% solutions (10 and 7, respectively). The maximum volume of foam surgeons were happy to use in one treatment session varied quite markedly (Fig. 1), 10 ml (14) and 12 ml (11) being the most common. There was no correlation between the surgeon's experience with foam and the volume of foam used.

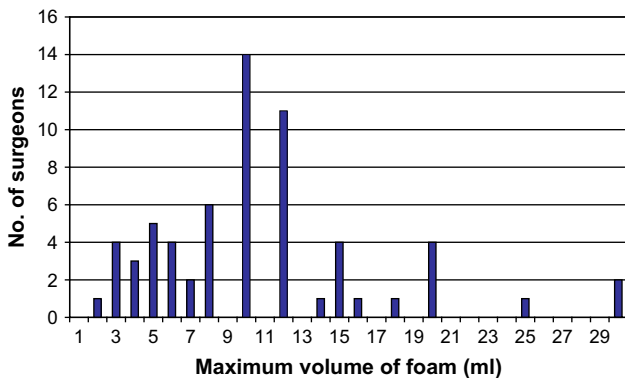


Fig. 1. The maximum volume of foam surgeons usually employed in one treatment session.

*Technique*

The vast majority of surgeons (58 of 62, 94%) usually cannulated the great saphenous vein (GSV) or small saphenous vein (SSV) under ultrasound guidance. Most (60 of 64, 94%) monitored the progress of foam injected into the vein using ultrasound imaging (Fig. 2). The leg was elevated before foam injection by 69% (43 of 62) and foam was milked along the vein using surface pressure by 68% (42 of 62). Sixty three percent (39 of 62) routinely blocked the sapheno-femoral or saphenopopliteal junction during foam injection. The commonest technique employed was to treat the main incompetent vein first, with a separate session for treatment of any remaining smaller varicosities: 62% (40 of 65 surgeons). Seventy-one percent of surgeons (46 of 65) varied the concentration of the foam used depending on target vein size.

*Post-treatment compression*

Most surgeons (55 of 69, 80%) employed compression bandaging after foam treatment; the remainder used graduated compression immediately. Most commonly used were Peha-Haft (Hartmann, Germany) (10 responses), Crepe (8) and Panelast (Lohmann & Rausch, Germany) (6) bandages. The duration of compression was variable but usually 1 (7 responses), 5 (9) or 7 (24) days. A few surgeons recommended patients stay in bandages for as long as a month (Fig. 3a).

The vast majority (62 of 69, 90%) advised patients to wear compression stockings after the first few days of compression bandaging. These were usually Class II compression stockings (39 of 61, 64%) or

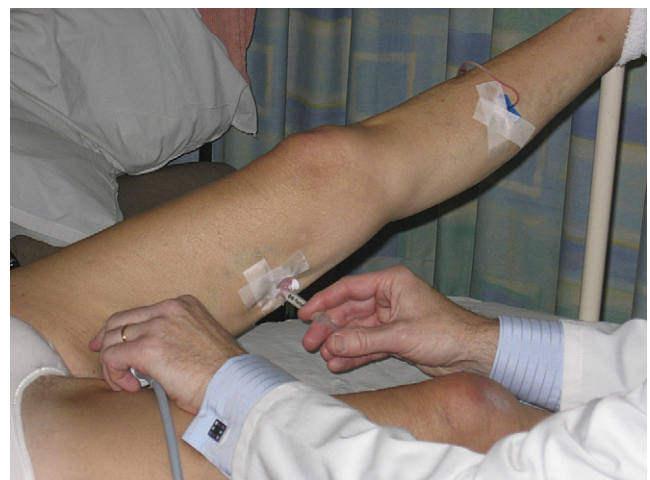

Fig. 2. Foam sclerosant injected via Venflon into the GSV under ultrasound control.

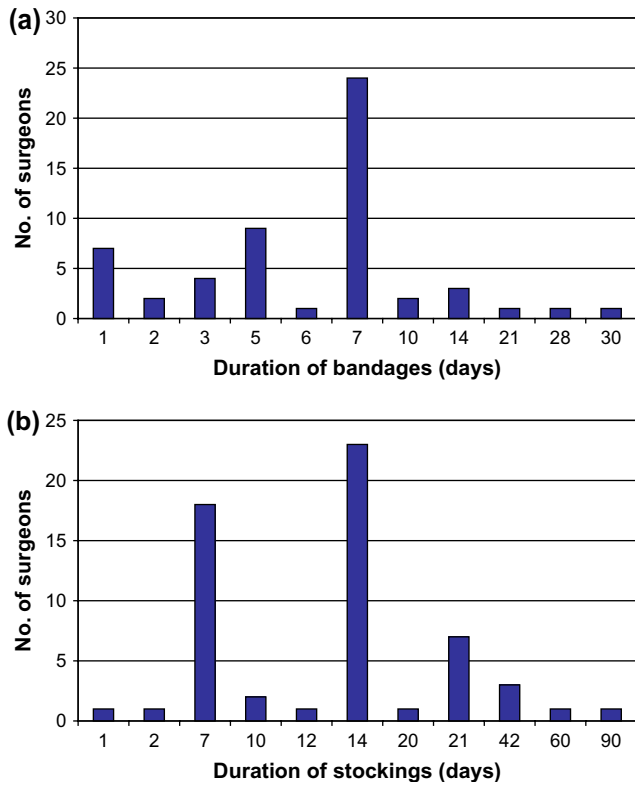


Fig. 3. The duration of (a) compression bandaging and (b) stocking use advised after foam sclerotherapy.

thrombo-embolic deterrent stockings (17 of 61, 28%). The recommended duration of compression varied, but was usually 7 (18 replies) or 14 (23) days. A few suggested remaining in stockings for as long as 3 months (Fig. 3b).

### Complications

Major complications were described infrequently. Sixteen percent (11) of surgeons had seen at least one episode of deep vein thrombosis (DVT). Twenty-one percent (15) had witnessed a transient visual disturbance. Two surgeons (3%) had seen a stroke and one (1%) a transient ischaemic attack (TIA). None had seen a pulmonary embolus or permanent visual disturbance.

The most commonly seen minor complication was skin staining (43, 61% of surgeons). Skin necrosis or ulceration was described by 17% (12). Three percent (2) had seen an allergic reaction. Other complications were recorded by 17% of surgeons and included phlebitis (5 surgeons), lumpiness (3), fainting (2), coughing (1), skin blistering (1), reticular varices (1) and recurrence (1).

### Discussion

When members of the Vascular Society of Great Britain and Ireland were last questioned about their use of sclerotherapy in 1998,<sup>6</sup> its use for varicose veins was decreasing and few surgeons (10 of 178) said they would use it in the presence of proximal saphenous incompetence. Liquid sclerotherapy in these patients gave poor results although it remained popular for treating telangiectasia. The technique of foam sclerotherapy, where liquid sclerosant is mixed with air, has since gained in popularity and appears to give better results than liquid sclerotherapy for patients with GSV incompetence.<sup>7,8</sup> Foam enables accurate injection of sclerosant under ultrasound guidance and has proved effective even in large varices.<sup>9</sup> The increased volume of foam displaces more blood, at a lower dose, thus making it potentially more efficacious. A number of authors have published encouraging results after foam sclerotherapy with up to 3 years follow-up.<sup>10–18</sup>

There was a relatively low response rate to this questionnaire. However, it may be that most of the vascular surgeons currently employing foam sclerotherapy responded. Non-responders may have been those without enthusiasm. A minimum of 70 surgeons use foam regularly. The widespread use of duplex ultrasound imaging, leg elevation and post-treatment compression were all in line with the recommendations of the 2003 European Consensus meeting.<sup>4</sup> However, the large volumes of foam used by some surgeons were concerning and were significantly higher than the 6–8 ml per session recommended by the Consensus group.

Three separate surgeons documented that they had seen a patient develop a stroke or TIA. Although impossible to get an accurate incidence from a survey, the study involved a total of 4536 patients treated with foam suggesting a maximum incidence of around one in 1500. Neurological complications were seen by both experienced and inexperienced users. There are two reported cases of stroke in the literature.<sup>5,19</sup> Both occurred in patients with a patent foramen ovale, but in only one was there convincing evidence that foam had been the cause (foam particles seen in the carotid artery after the injection of 20 ml foam).<sup>5</sup> The other case followed the use of liquid polidocanol. Although rare, this is a serious complication from an elective procedure done often for moderate symptoms. A prospective registry of significant complications from foam sclerotherapy, with details of the technique used in each case, would be a useful step towards gathering evidence about how complications might be avoided. The significance of major complications

in the context of treating patients with uncomplicated varicose veins requires debate. Other reported complications in this survey were similar to those described in the literature, although in the authors' experience a degree of phlebitis and lumpiness in the treated vein is far more common than reported here.

The REACTIV trial<sup>20</sup> demonstrated that both surgery and sclerotherapy are cost-effective treatments for varicose veins. There are a number of new and evolving office treatments for varicose veins and controlled trials comparing the different methods are needed urgently.<sup>21,22</sup>

### References

- 1 WINTERBORN RJ, EARNSHAW JJ. Crossectomy and great saphenous vein stripping. *J Cardiovasc Surg (Torino)* 2006;**47**:19–33.
- 2 JAN-CHRISTOPH GR, WOLLMAN MD. The history of sclerosing foams. *Dermatol Surg* 2004;**30**:694–703.
- 3 TESSARI L, CAVEZZI A, FRULLINI A. Preliminary experience with a new sclerosing foam in the treatment of varicose veins. *Dermatol Surg* 2001;**27**:58–60.
- 4 BREU F-X, GUGGENBICHLER S. European consensus meeting on foam sclerotherapy, April, 4–6, 2003, Tergernsee, Germany. *Dermatol Surg* 2004;**30**:709–717.
- 5 FORLEE MV, GROUDEN M, MOORE DJ, SHANIK G. Stroke after varicose vein foam injection sclerotherapy. *J Vasc Surg* 2006;**43**:162–164.
- 6 GALLAND RB, MAGEE TR, LEWIS MH. A survey of current attitudes of British and Irish vascular surgeons to venous sclerotherapy. *Eur J Vasc Endovasc Surg* 1998;**16**:43–46.
- 7 YAMAKI T, NOZAKI M, IWASAKA S. Comparative study of duplex-guided foam sclerotherapy and duplex-guided liquid sclerotherapy for the treatment of superficial venous insufficiency. *Dermatol Surg* 2004;**30**:718–722.
- 8 HAMEL-DESNOS C, DESNOS P, WOLLMAN J-C, OUVRY P, MAKO S, ALLAERT F-A. Evaluation of the efficiency of polidocanol in the form of foam compared with liquid form in sclerotherapy of the greater saphenous vein: initial results. *Dermatol Surg* 2003;**29**:1170–1175.
- 9 BARRETT JM, ALLEN B, OCKELFORD A, GOLDMAN MP. Microfoam ultrasound-guided sclerotherapy treatment for varicose veins in a subgroup with diameters at the junction of 10 mm or greater compared with a subgroup of less than 10 mm. *Dermatol Surg* 2004;**30**:1386–1390.
- 10 KANTER A, THIBAUT P. Saphenofemoral incompetence treated by ultrasound-guided sclerotherapy. *Dermatol Surg* 1996;**22**:648–652.
- 11 CABRERA J, CABRERA Jr J, GARCIA-OLMEDO MA. Treatment of varicose long saphenous veins with sclerosant in microfoam form: long-term outcomes. *Phlebology* 2000;**15**:19–23.
- 12 CAVEZZI A, FRULLINI A, RICCI S, TESSARI L. Treatment of varicose veins by foam sclerotherapy: two clinical series. *Phlebology* 2002;**17**:13–18.
- 13 BARRETT JM, ALLEN B, OCKELFORD A, GOLDMAN MP. Microfoam ultrasound-guided sclerotherapy of varicose veins in 100 legs. *Dermatol Surg* 2004;**30**:6–12.
- 14 ALOS J, CARRENO P, LOPEZ JA, ESTADELLA B, SERRA-PRAT M, MARINEL-LO J. Efficacy and safety of sclerotherapy using polidocanol foam: a controlled clinical trial. *Eur J Vasc Endovasc Surg* 2006;**31**:101–107.
- 15 DARKE SG, BAKER SJA. Ultrasound-guided foam sclerotherapy for treatment of varicose veins. *Br J Surg* 2006;**93**:969–974.
- 16 COLERIDGE-SMITH P. Chronic venous disease treated by ultrasound guided foam sclerotherapy. *Eur J Vasc Endovasc Surg* 2006;**32**:577–583.
- 17 BOUNTOUROGLOU DG, AZZAM M, KAKKOS SK, PATHMARAJAH M, YOUNG P, GEROUKAKOS G. Ultrasound-guided foam sclerotherapy combined with saphenofemoral ligation compared to surgical treatment of varicose veins: early results of a randomised controlled trial. *Eur J Vasc Endovasc Surg* 2006;**31**:93–100.
- 18 MYERS KA, JOLLEY D, CLOUGH A, KIRWAN J. Outcome of ultrasound-guided sclerotherapy for varicose veins: medium term results assessed by ultrasound surveillance. *Eur J Vasc Endovasc Surg* 2007;**33**:116–121.
- 19 HANISCH F, MULLER T, KRIVOKUCA M, WINTERHOLLER M. Stroke following variceal sclerotherapy. *Eur J Med Res* 2004;**9**:282–284.
- 20 MICHAELS JA, CAMPBELL WB, BRAZIER JE, MACINTYRE JB, PALFREYMAN SJ, RATCLIFFE J *et al.* Randomised clinical trial, observational study and assessment of cost-effectiveness of the treatment of varicose veins (REACTIV trial). *Health Technol Assess* 2006;**10**:1–196.
- 21 VAN RIJ A. Varicose veins. *Br J Surg* 2006;**93**:131–132.
- 22 CAMPBELL WB. Varicose veins and their management. *BMJ* 2006;**333**:287–292.

Accepted 25 March 2007

Available online 15 May 2007